

jcd

vol. 27 issue 2

Journal of Cosmetic Dentistry

Myths vs. Realities: Prepped and Prep-Less Veneers

Drs. Brian LeSage and Dennis Wells

Multi-faceted Ceramic Solutions—Earn Free CE!

Matthew Roberts, CDT, and Drs. Franklin Shull, James Fondriest, and Thomas Trinkner

Solving a Patient's Precise Request with Veneers

Dr. W. Johnston Rowe, Jr. and Wayne Payne

SUMMER 2011

AAFD American Academy
of Cosmetic Dentistry®

Enhancing Nature to Achieve Patients' Desires

A Smile Makeover Utilizing Porcelain Veneers

W. Johnston Rowe, Jr., DDS, AAACD
Wayne B. Payne, AAACD

Introduction

Today's esthetically driven dental consumers can be very exacting with regard to the results they expect from their cosmetic dentist. Advances in cosmetic dentistry techniques and materials have provided clinicians with the armamentarium to meet virtually any reasonable request with incredible accuracy. Excellent communication between patient, dentist, and laboratory technician, coupled with meticulous planning and precise execution of the plan by all parties, yields excellent results. Porcelain veneers are often the most beautiful and most durable esthetic enhancement a dentist can offer a patient. When executed properly, porcelain veneers can often be mistaken for "perfect" natural teeth.

CLINICAL COVER STORY



Figure 1a

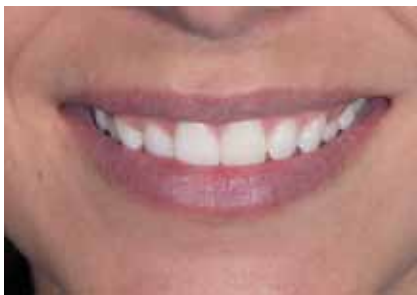

Figure 1b

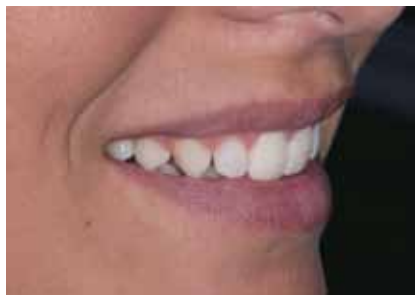

Figure 1c

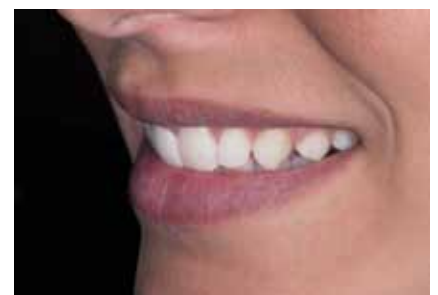
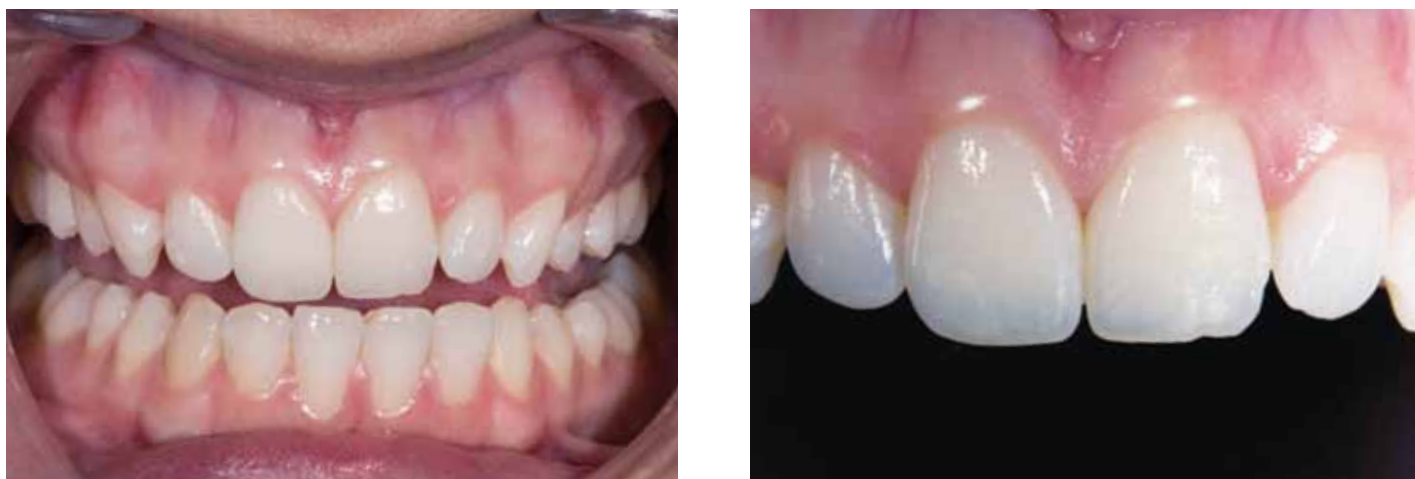
Figure 1d

Figures 1a-1d: Pre-restorative full-face images demonstrate the patient's concerns with the general shape and shade of her teeth. Note the irregular gingival heights and deficient buccal corridors.

When executed properly, porcelain veneers can often be mistaken for "perfect" natural teeth.



Figures 2a & 2b: Pre-restorative retracted 1:1 and 1:2 views show the developmental malformation of the distal-incisal edge of #9 and the poor positioning and shape of the canines and laterals, resulting in improper incisal embrasure form.

Case Presentation

Chief Complaint and History

The patient was a 29-year-old female in excellent health. She stated she had annual dental cleanings, had whitened her teeth in the past, and had no other particular dental concerns other than the esthetic appearance of her smile. The patient was a successful pageant contestant and was very specific regarding her complaints about her smile. She was particularly unhappy with the general shape and shade of her teeth (Figs 1a-1d), did not like the shape or positioning of her canines, and was concerned about the developmental malformation of the distal incisal angle of #9 (Figs 2a & 2b). She noted her deficient buccal corridors were an issue by explaining that her smile did not “fill her mouth.”¹

She further stated she did not want an “artificial”-looking smile and that achieving a beautiful, natural result was paramount; she had no desire to pursue orthodontic options.

A full-mouth series of periapical radiographs was made of the patient's teeth and no pathology was noted. Occlusion was also evaluated to rule out any possible traumatic interferences

that would affect the longevity of new restorations.² Canine guidance was observed without noting any posterior excursive interferences. A small chip was noted on the mesial incisal edge of #24 and, after questioning, was determined to be the result of biting down on a sewing needle several years in the past.

The clinical examination revealed a Class II molar and canine relationship with no significant occlusal interferences (Figs 3a & 3b). Evidence of mild wear was found on the patient's anterior and molar teeth (Figs 4a & 4b) and, after evaluation of occlusion, it was determined that this process of pathologic wear appeared to be controlled by the nightly wearing of a hard, flat plane, acrylic occlusal guard. The patient exhibited no symptoms of any temporomandibular joint (TMJ) disorder and appeared asymptomatic during a TMJ evaluation.²

Diagnosis and Treatment Plan

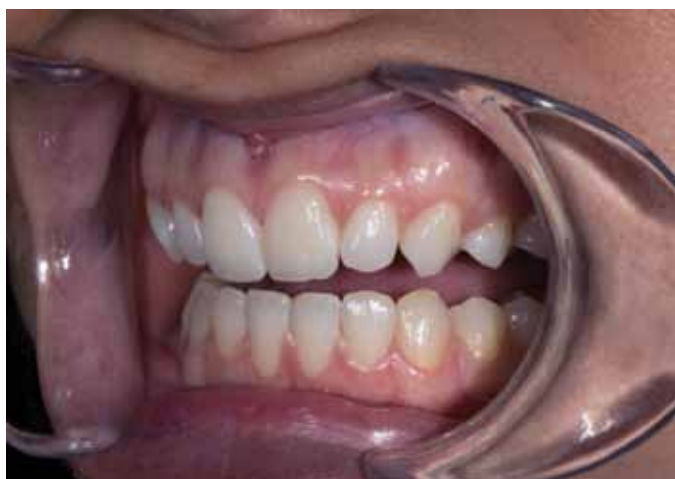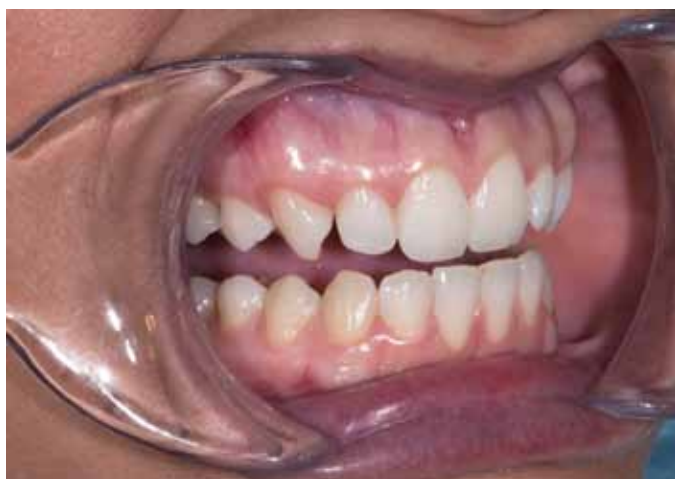The patient's dentition exhibited mild wear, unesthetic tooth shape, and poor tooth size proportions.¹ Some crowding was also present, with a slightly constricted arch form in the premolar areas of the maxilla.¹ Several areas of gingival asymmetry were noted. The patient had

a Class II occlusion with a history of mild pathologic wear; any parafunction was controlled by nightly wear of an occlusal guard.

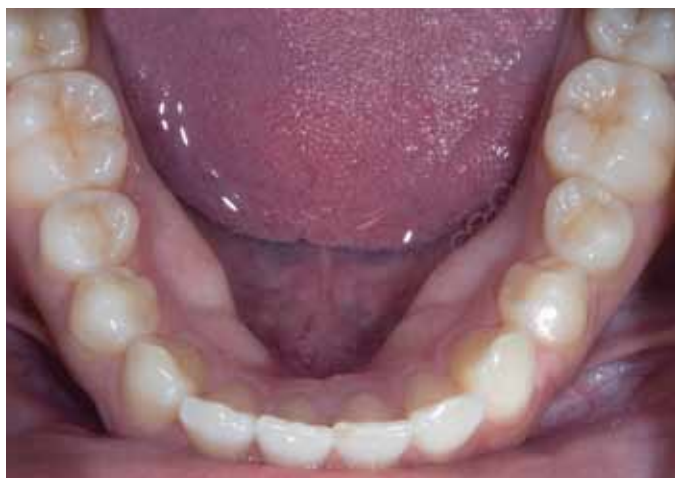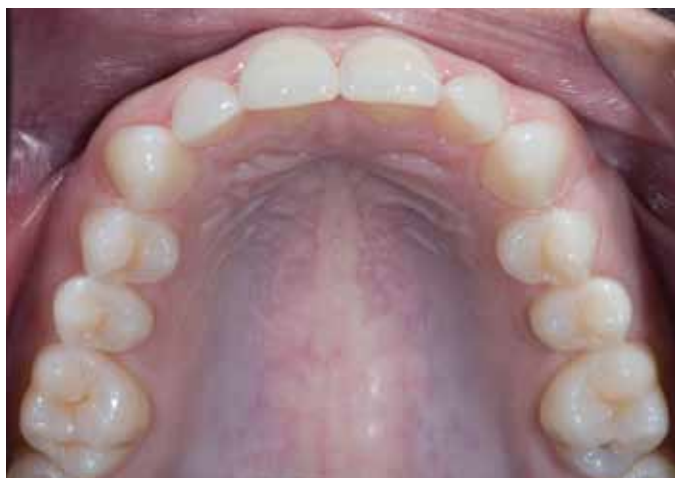Following discussion of esthetic restorative options for her smile, the patient elected to pursue a treatment plan that included tray bleaching of her maxillary and mandibular teeth, followed by treatment of #4-13 with minimal preparation porcelain veneers. She was excited by the idea of having her teeth restored in a conservative manner, without having to pursue prolonged orthodontic treatment.

In addition to being unhappy with the size, shape, and color of her front teeth, she did not like the transition in her smile from the canines to the premolars and wanted to treat the premolars to blend appropriately with her anterior teeth (Figs 2a, 3a & 3b, 5a & 5b). A natural, beautiful result was the patient's primary goal. She chose not to address the chipped incisal edge of #24 (restoration with composite filling material was recommended). Proper care for the future porcelain restorations was discussed, including the nightly wearing of a maxillary full arch, hard protective occlusal guard; and the importance of optimal maintenance,

CLINICAL COVER STORY



Figures 3a & 3b: Pre-restorative right and left lateral retracted 1:2 views show improper progression of incisal embrasures, Class II canine relationship, and poor transition from anterior to posterior teeth.



Figures 4a & 4b: Maxillary and mandibular pre-restorative occlusal views demonstrate mild wear on the anterior and molar teeth.

including regular cleanings and examinations was stressed.³

A comprehensive set of records was made of the patient's preoperative condition to allow for proper communication between the dentist and the ceramist. A laboratory prescription was prepared, including the patient's complaints and proposed smile changes. In addition to the information provided to the ceramist, the operator called the ceramist to discuss the fine points of the case (clarification of the specific patient desires and discussion of the restorative material and technique

planned for the case). Due to the lingual inclination of the patient's maxillary teeth inherent with her Class II occlusal setup, minimal preparation veneers were indicated. Alginate impressions of both the maxillary and mandibular arches were made and study models were fabricated in die stone.³⁻⁶ Polyvinyl siloxane (PVS) impressions were made of both arches and a Megabite PVS bite registration (Discus Dental; Culver City, CA) was made, along with numerous digital photographs, meticulously documenting the preoperative shade, texture, and shape of surrounding

teeth.^{3,4,6,7} A facebow transfer was done, as well. All records were sent to the laboratory, where the study models were mounted on a semi-adjustable articulator, and teeth ##4-13 were waxed to full contour by the ceramist. A putty PVS stent was then formed to fabricate an incisal reduction matrix. Custom whitening trays were also fabricated from the study models and were delivered, at the initial records appointment, with 10% Opalescence PF whitening gel (Ultradent; South Jordan, UT) and instructions for use.

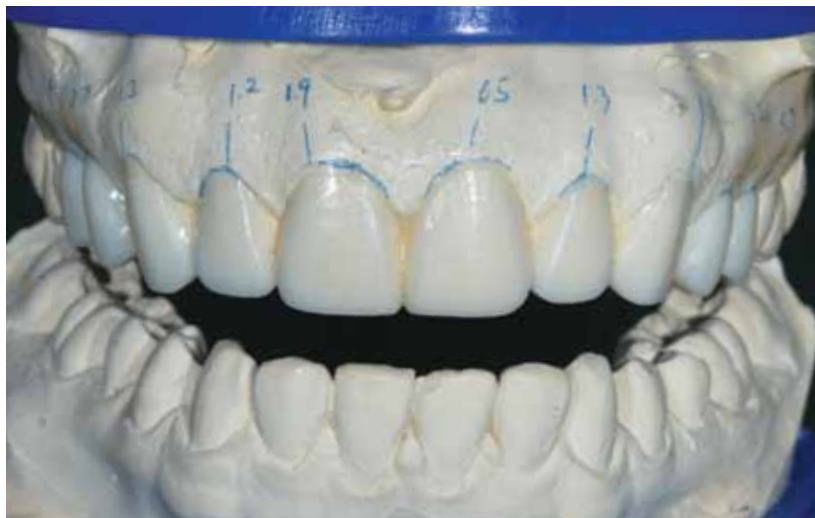

Figure 6: Waxed-up study casts demonstrate a blueprint for restorative success.

Treatment

The patient reviewed the diagnostic wax-up of her smile on the day of her preparation appointment. She was able to view and approve the waxed teeth presented on mounted study models prior to any preparation of her teeth^{3,4} (Figs 6, 7a & 7b, 8a & 8b, & 9). Following approval of the wax models, shade selection was performed immediately to ensure proper match of hue, chroma, and value, prior to any dehydration of the teeth that would occur during the treatment process.^{3,4} Under color-corrected lighting, digital photographs were made from multiple angles, with at least two shade tabs per photograph, to assist in shade matching and color mapping.⁴ The dentist also provided a shade map for the ceramist, to be used as a complementary guide with the photographs.

Profound anesthesia was obtained through the use of a topical anesthetic followed by injection of articaine with 1:100,000 epinephrine in the areas of ##4-13. Tissue sculpting was performed with a Waterlase ErCr: YSGG laser (Bio-lase; Irvine, CA) to even gingival levels on ##5-8 and #12 (Figs 6, 8a & 8b). Careful attention was paid in measuring tissue to be removed, coupled with preoperative bone sounding to avoid

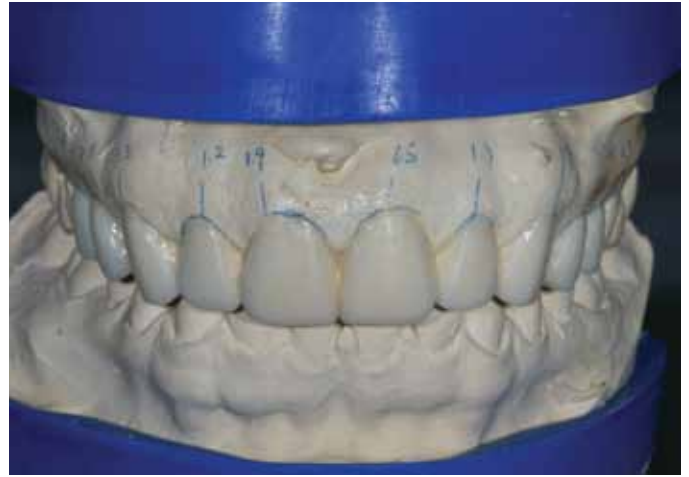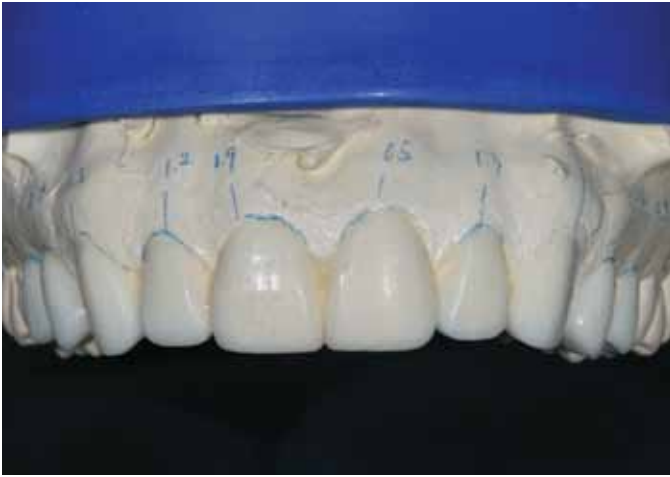invasion of biologic width.^{3-6,8} A clear plastic surgical guide was used to gauge the tissue reduction as marked on the diagnostic wax-up.

Initial tooth preparation was completed with a 2000.10 Two Stripper super-coarse grit diamond bur (Premier Dental; Plymouth Meeting, PA) in a high-speed handpiece under copious water spray. Due to the size and positioning of the patient's teeth, minimal tooth reduction of the enamel was required. Adequate incisal (1.5 mm) and facial (.75 mm) porcelain thickness was needed to provide room for layering, slight color change, and addition of incisal effects in the porcelain.^{3,4} A well-defined cervical margin was established with a 703.8F diamond bur (Premier Dental) to provide for a positive veneer stop and a precise porcelain to tooth interface that would be smooth and easily cleanable.^{3,4} Careful attention was paid to prepare the margin deep enough to allow for appropriate thickness of porcelain for strength, without compromising proper emergence profile. Abrasive discs (Cosmedent; Chicago, IL) in a slow-speed handpiece were used to smooth the preparations and eliminate any sharp angles that could cause internal stress points in the porcelain restorations.^{3,4} Appropriate incisal reduction

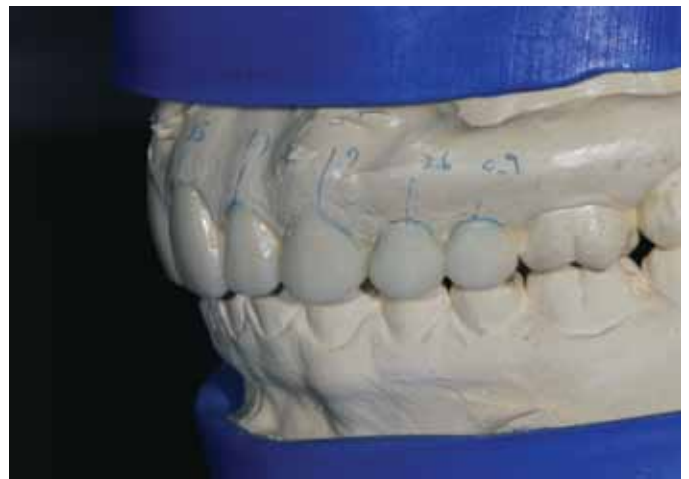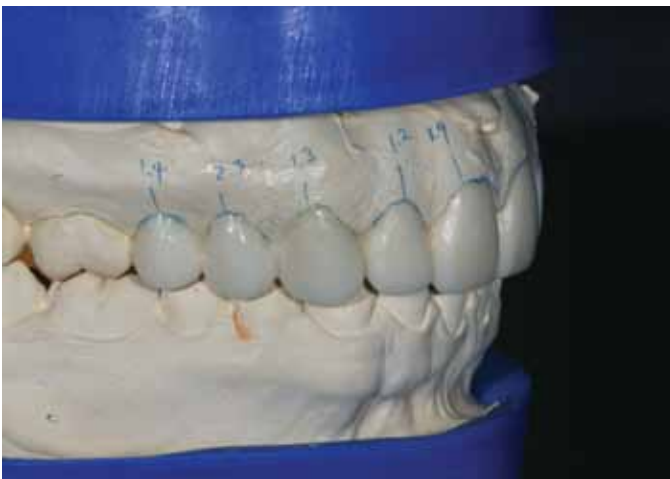was confirmed with the lingual and incisal PVS stent. Photographs of the preparations were made and a preparation shade of st9 (Ivoclar Vivadent; Amherst, NY) was observed and recorded to be communicated to the ceramist. Expa-syl gingival retraction paste (Kerr; Orange, CA) was expressed around all gingival margins to provide hemostasis and adequate tissue reflection for the master impression. After three minutes, the paste was rinsed away with a copious, forceful water spray. The preparations were dried and a master polyvinyl impression was made with Honigum Light and Heavy impression material (DMG America; Englewood, NJ). A Megabite stick bite of the prepared teeth in centric occlusion (CO) was made and photographed. All impressions were disinfected and sent to the laboratory with the photographic records and instructions for the ceramist.

The patient's teeth were then lubricated with a thin layer of glycerin gel to minimize any chance of adhesion during provisional fabrication. The PVS stent made from the diagnostic wax-up was filled with BL Luxatemp (DMG America), placed over the prepared teeth and allowed to cure. After approximately one minute, the stent was gently

CLINICAL COVER STORY



Figures 7a & 7b: Measurements for tissue recontouring were marked on the study models and transferred to the mouth for precise tissue sculpting.



Figures 8a & 8b: Right and left lateral views of wax-up demonstrate corrected progression of embrasures and gingival contours.

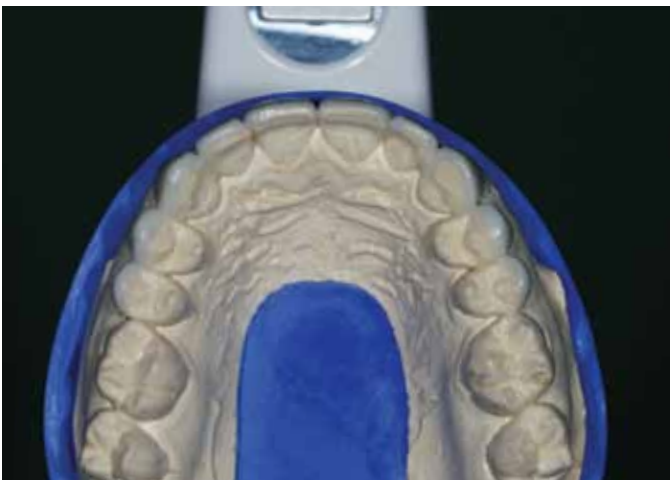

Figure 9: Occlusal view of maxillary wax-up demonstrates corrected arch form and proper facial embrasures.

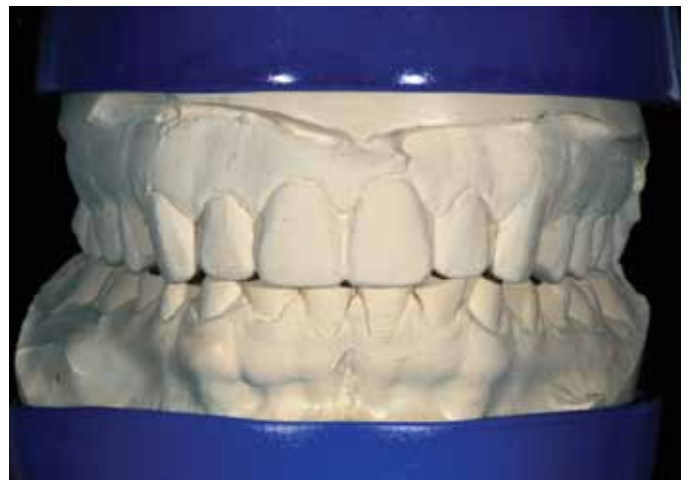

Figure 10: Temporary model articulated.

CLINICAL COVER STORY

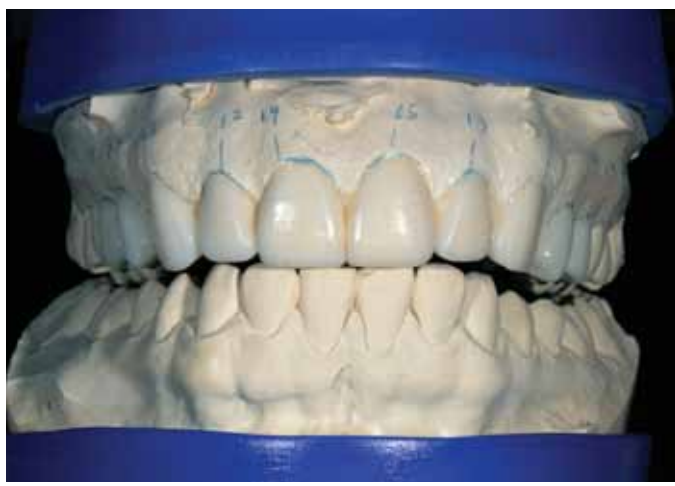

Figure 11: Wax-up articulated.

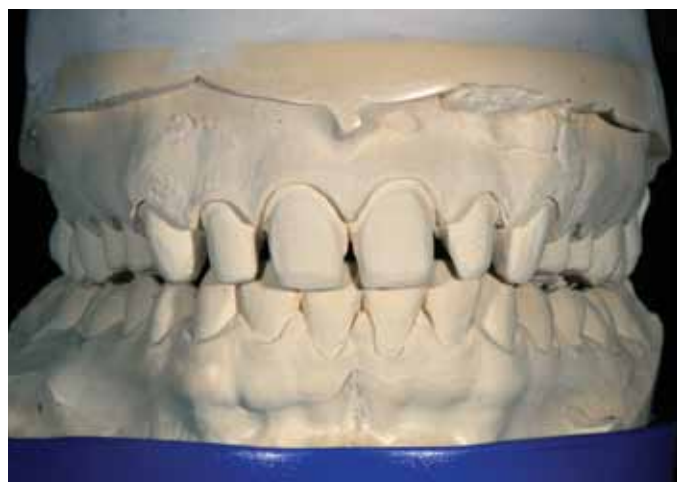

Figure 12: Solid model articulated.

removed, with the veneer provisionals remaining inside. Excess material was scaled away from the teeth and the teeth were cleaned with pumice and Consepis chlorhexadine (Ultradent). The provisionals were removed from the stent and trimmed. The provisional restorations were then seated with Optibond FL resin (Kerr) and cured for five seconds on each tooth with a Fusion LED curing light (DentLight; Richardson TX). Excess material was removed with a scaler and a #12 scalpel blade, and the provisionals were smoothed and finished with abrasive discs (Cosmedent) and a rubber cup polisher (Cosmedent). Occlusion was verified and checked and the patient was scheduled for a postoperative check 24 hours later.

The 24-hour postoperative check was particularly important because it was the patient's first opportunity to evaluate the proposed shapes and contours of her new teeth without being anesthetized. The check began with an esthetic and phonetic evaluation by the patient and the doctor. The patient reviewed and approved the shape of her provisional restorations and the shade tabs selected at the prior appointment. Proper occlusion and anterior guidance were confirmed. Photographs were taken of the approved provisional restorations and shade tabs were made. Other

provisional records were made, including a stick bite in CO and a polyvinyl impression of the approved provisionals. All records were disinfected and sent to the ceramist, accompanied by a complete laboratory prescription and all photographs taken to that point. The ceramist was instructed to use the impression of the approved provisionals as a guide for the final shape, size, and contour of the porcelain restorations.

Laboratory Phase

During the three-week provisional phase following the master impression appointment, the patient was able to further reevaluate the provisional restorations. If she had requested any changes, they would have been communicated to the ceramist during this period. No changes were requested during this time.

The patient's approved basic shade choice of BL2 (Ivoclar Vivadent) with a slight fade to BL3 at the gingival (more on #7 and #10 than on the centrals), and a cervical BL4 on the canine teeth was communicated to the ceramist on the laboratory prescription. A moderate incisal translucency pattern was requested with natural gingival staining and a polished gloss lightly textured finish. Additional information sent to the laboratory included the following:

- shade map (proposed)

- digital photographs: preoperative, prepared, and provisionalized
- digital photographs of teeth with shade guides: preoperative, prepared, and provisionalized
- stick bite registrations with photographs: preoperative, prepared, and provisionalized
- master PVS impression of prepared teeth (two sets)
- opposing PVS impression of mandibular teeth
- PVS impression of maxillary provisional restorations
- specific written details of case goals with special emphasis on shade.

At this time, a prescription for 10 Authentic porcelain veneers (Jensen Industries; North Haven, CT) was written. On receipt of the case, the records were reviewed by the ceramist and the material choice on the prescription was confirmed during a telephone conversation. Shape, shade, and characterization were discussed again and finalized in the planning stage.

The laboratory received PVS impressions of the preparations, opposing arch, and approved provisional restorations, as well as a stick bite, bite records, and detailed prescription of the patient's desired restorative results. The dentist and ceramist discussed and agreed to use a pressed ceramic material (Authentic) for the restorations.

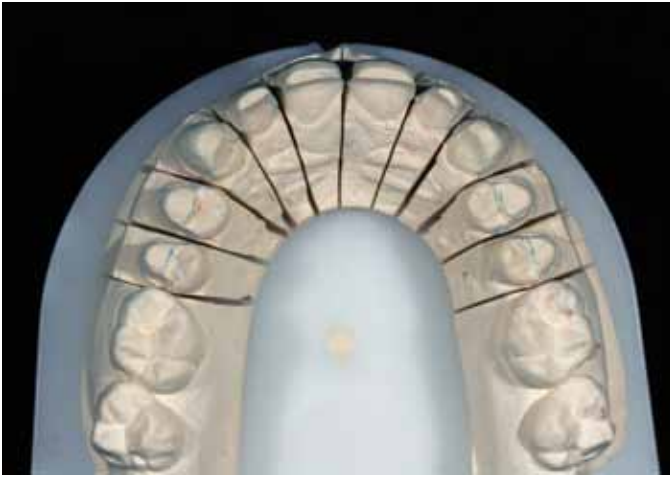

Figure 13: Die model cut.

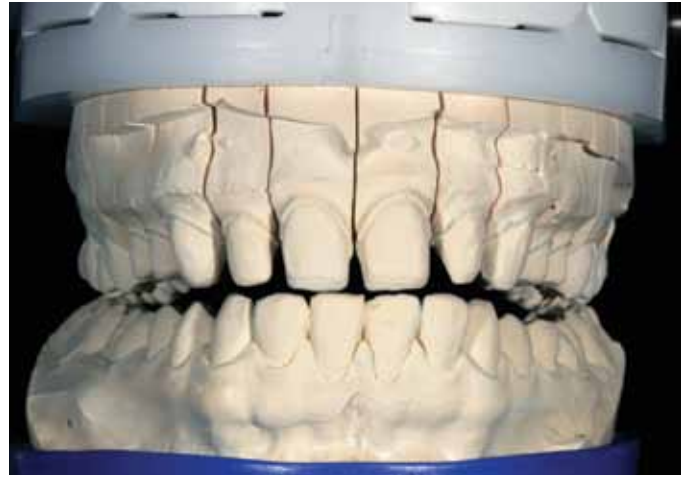


Figure 14: Die model articulated.

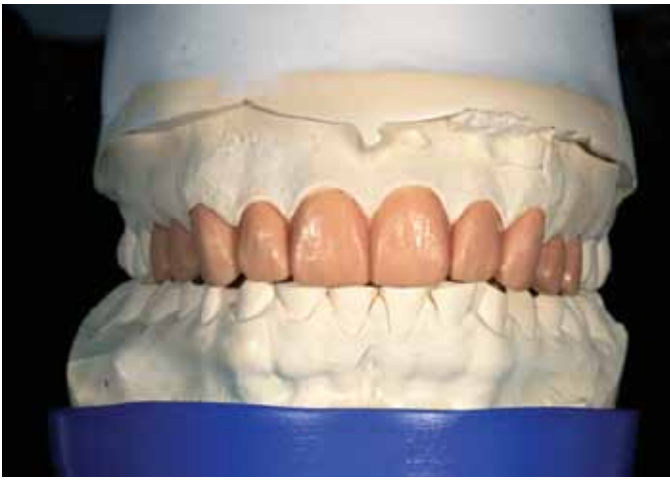

Figure 15: Wax injection on solid model articulated.

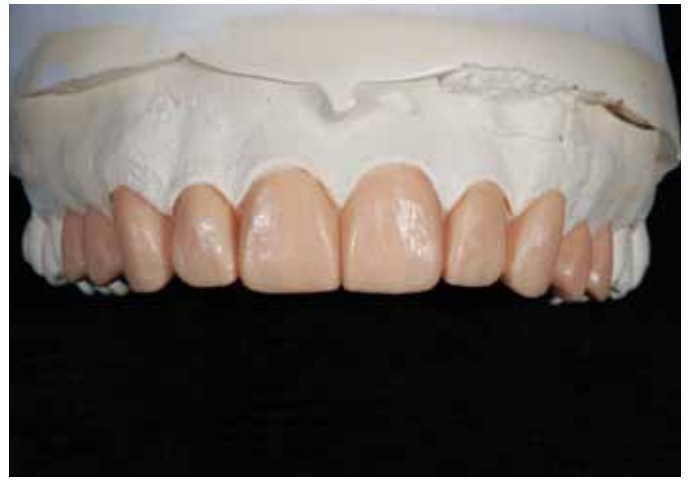

Figure 16: Wax injection on solid model.

Models were poured in ivory diamond die stone (Hi-Tec Dental; Greenback, TN), and the master impression was pinned (Giroform system, Amann Girrbach America; Spring Hill, FL). A solid model was created for tissue form.

The case was articulated using bite records on a Stratos 200 (Ivoclar Vivadent). The die, solid, and provisional models were all mounted and cross-mounted to check for accuracy (Figs 10-12).

A silicone matrix was made (Sil-Tech, Ivoclar Vivadent) from the patient's approved temporary model. This tooth

form was transferred to the solid die model using a wax injector (Pro-Craft, Grobet USA; Carlstadt, NJ) with beige Thowax (Yeti Dental; Engen, Germany). The wax was checked for length, width, function, and deflective and reflective line angles, as well as gingival emergence (Figs 13-16).

The case was sliced into single units and the margins sealed, after which it was sprued and invested (Microstar HS Investment, Jensen Industries). It was set for 17 minutes before being placed in an 855° C burnout furnace and burned out for one hour. The case was

pressed using a W+ ingot in a pressing furnace (EP 600, Ivoclar Vivadent) to 925° C. Once cooled, it was devested using 50- μ glass beads.

Units were cut off the sprues using a #911.104.220 diamond disc (Komet USA; Rock Hill, SC). Marginal integrity and contacts were established using a #850.HP.016 tapered bur (Komet) and checked with Accufilm 2 (Parkell; Edgewood, NY). Occlusion was also checked for accuracy using Accufilm and burs (Fig 17).

At this point, photographs of the patient and the model were scrutinized

CLINICAL COVER STORY

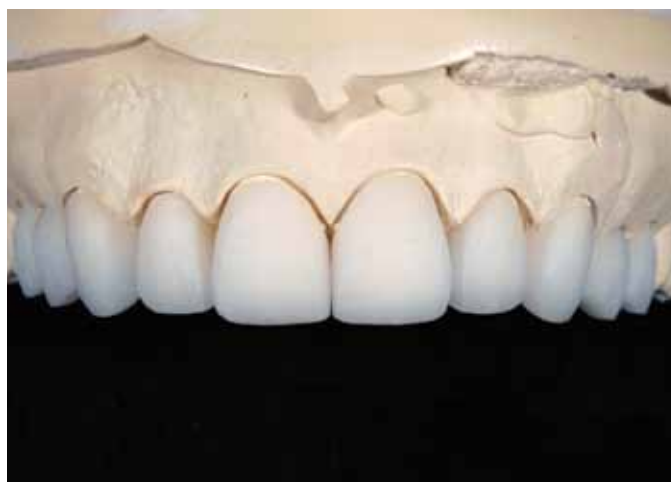

Figure 17: After pressing, seated on solid model.

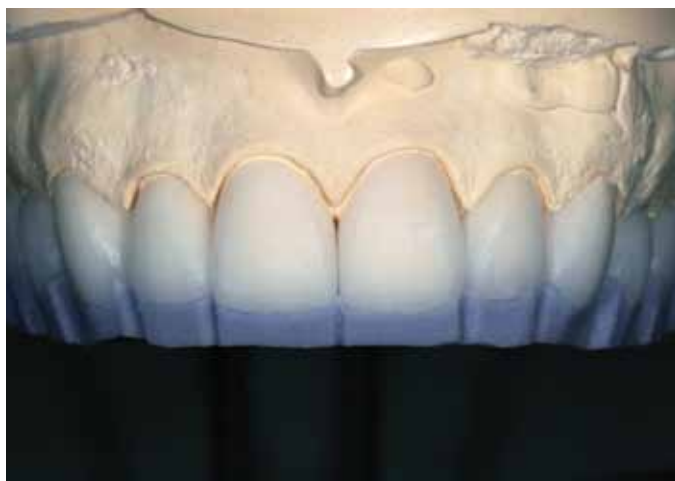


Figure 18: Veneers contoured with lingual matrix.

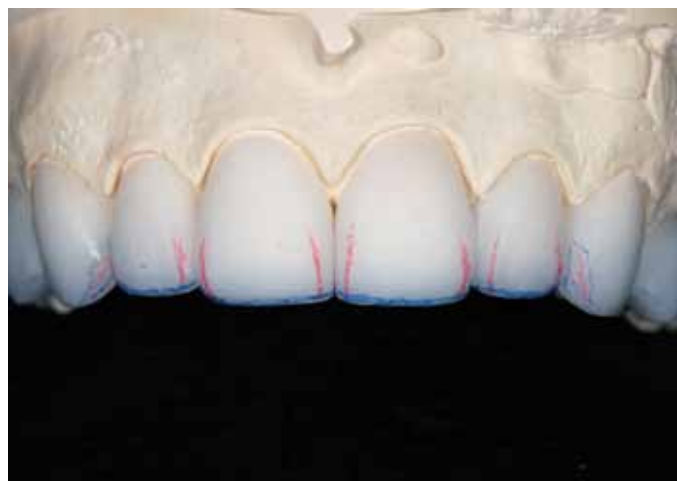

Figure 19: Cutback map defined.

to ensure that the shape and labial contours of the final restorations would match the patient's desired results. A lingual matrix was made of the patient's approved temporary model (Sil-Tech), and the lingual surface of the matrix was sprayed with pink fit checker (Quick-check Red, Vacalon; Pickerington, OH). The restorations were adjusted to fit the matrix, after which they were cleaned and a new matrix of the restorations was made on the solid model (Fig 18).

It is important to note that working from the patient's approved temporary model is significant to achieving successful outcomes because this model

represents what the patient expects and has verbalized as acceptable in terms of esthetics, fit, function, color, shape, etc. In esthetic dentistry, the ball can be dropped when a patient-approved temporary is not followed.

Therefore, tracing the approved temporary utilizing the lingual/incisal matrix allows for an exact duplication of the lingual side and incisal edge of the patient's approved provisional, which are key to the bite, function, and phonetics experienced in the final restorations. Building a case using the incisal/lingual matrix as a guide ensures that the final restorations will mimic what

the patient has been experiencing during the temporary period and helps to ensure predictability and success.

The restorations were then cut back for porcelain layering using a diamond-impregnated rubber wheel (Meister Point SD-61, Noritake Dental; Aichi, Japan). The incisal edge was dropped in .5 mm on ##7-10 and indicated with blue pencil. The mesial line angles of #6 and #11 were beveled and marked in blue and red. The mesial and distal grooves also were created for ##7-10, and areas to receive incisal effects were marked in red (Fig 19).

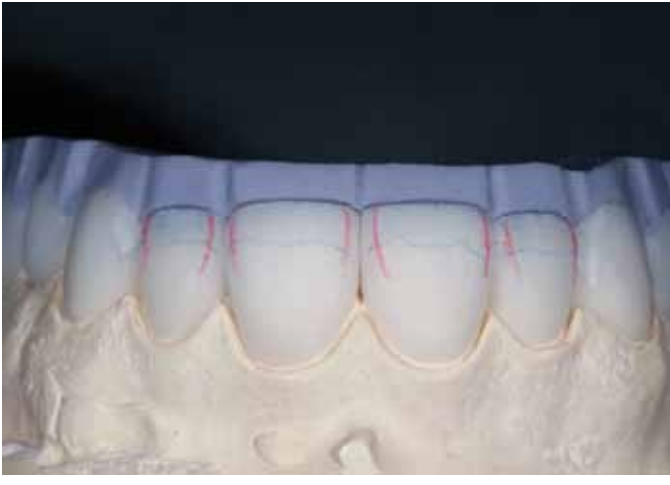


Figure 20: Cutback started, incisal reduced.

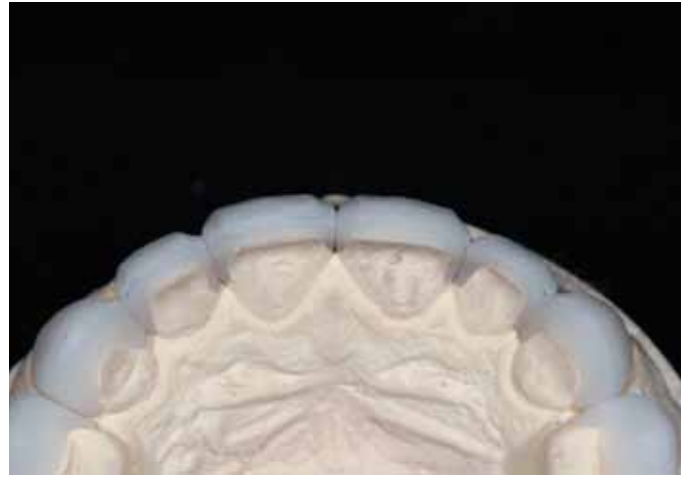

Figure 21: Incisal view showing mesial and distal grooves; incisal bevel from lingual of incisal edge to facial.

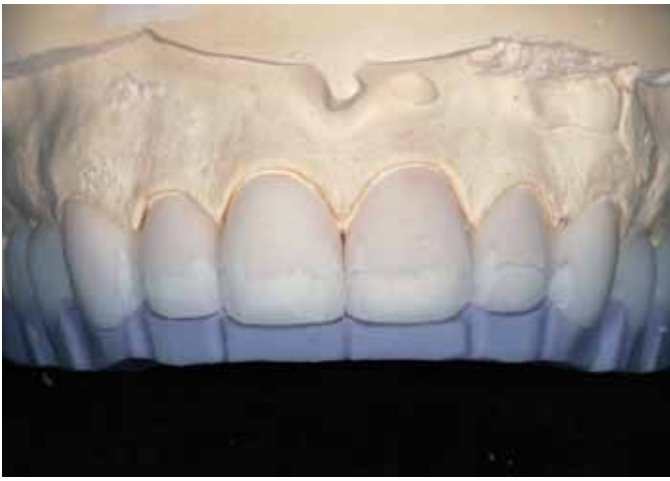

Figure 22: Labial view showing length of incisal blend.

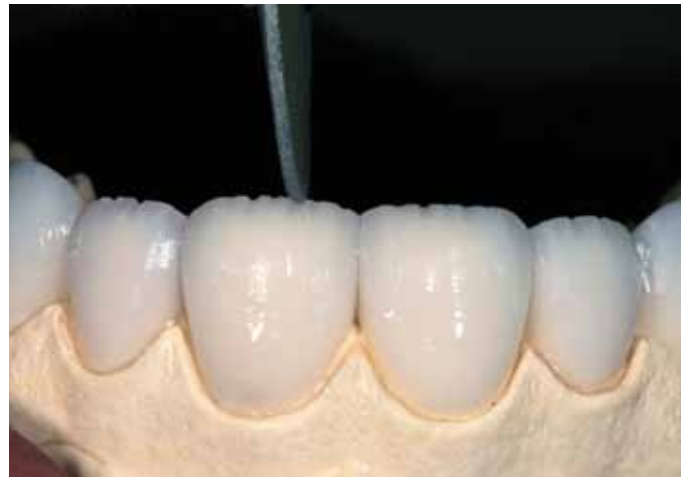

Figure 23: View of mamelon cutback; porcelain wetted to show depth of cutback.

The blue line on the incisal edge and the desired length of the incisal blend were then beveled at a 45-degree angle and checked into the matrix for appropriate depth (Figs 20 & 21). The key to establishing lifelike, subtle effects is to always refer to the matrix and ensure that all cutbacks are identical in each tooth (Fig 22).

To create the mamelon effect, each tooth was divided into three sections, divided into smaller sections, and then checked with the matrix for uniform thickness. The outside labial surface was decreased by .3 mm to .5 mm,

feathering out to the margins to enable porcelain layering over the entire length of the restorations (Fig 23). The units were then sandblasted at 20 psi to clean the surface.

Very highly fluoresced stains (Authentic) were applied internally using an S1 stain brush (Shofu Dental; San Marcos, CA) to mimic nature (Fig 24). Shade A and white stains were mixed 50/50, with the resulting color used for the mamelons. Shade B stain was lightly used in the gingival one-fourth and interproximal areas. Fluorescent Blue stain was used in the mesial and distal

grooves and very lightly across the incisal edge of the mamelon cutback.

After application, the stained restorations were fired in an oven (P500, Ivoclar Vivadent) to 735° C, holding for one minute in air and no vacuum. The stains were checked to ensure symmetry (Fig 25), and adjustments were made, if necessary.

A P7 brush (Shofu) was used to start the buildup. Using the incisal/lingual matrix lubricated with ceramic separating liquid (Ivoclar), the porcelain buildup was initiated with a 50/50 mix of Opal 1 and Opal 2, Opal 2 alone,

CLINICAL COVER STORY

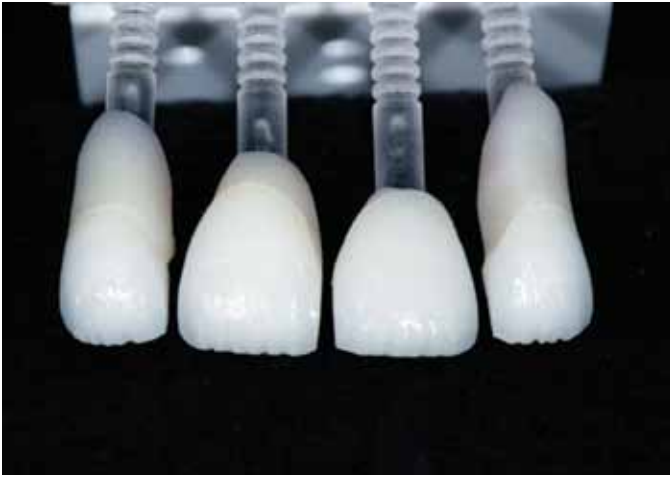


Figure 24: Stain applied.

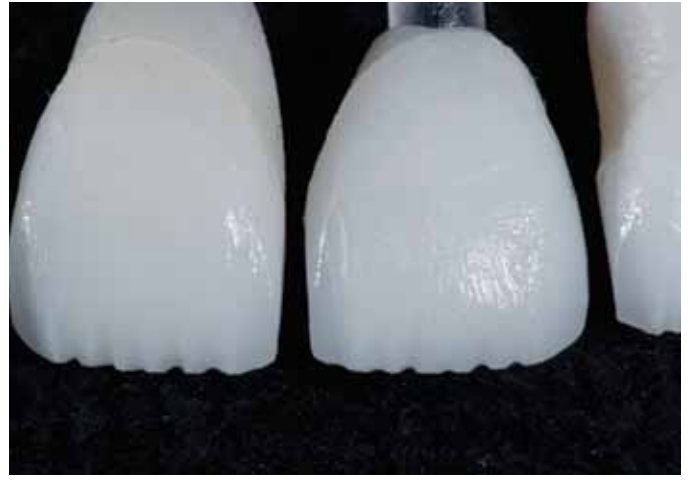

Figure 25: Close-up image of stain application.

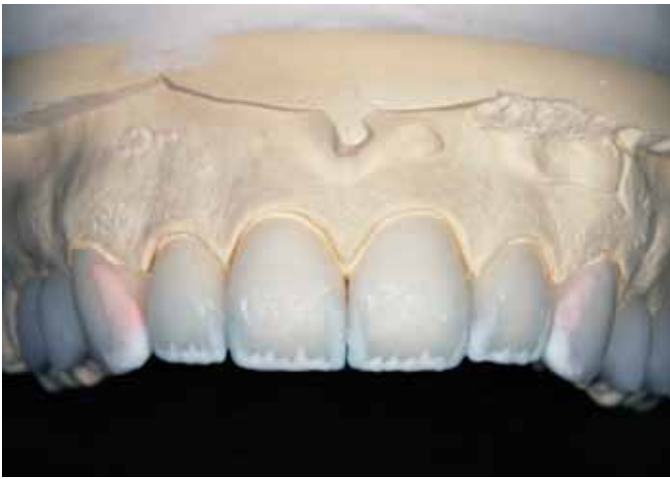

Figure 26: First layer of porcelain started. Pink = 50% Opal 1 and 50% Opal 2; blue = Transparent Blue Fluorescent; white = Opal 2.

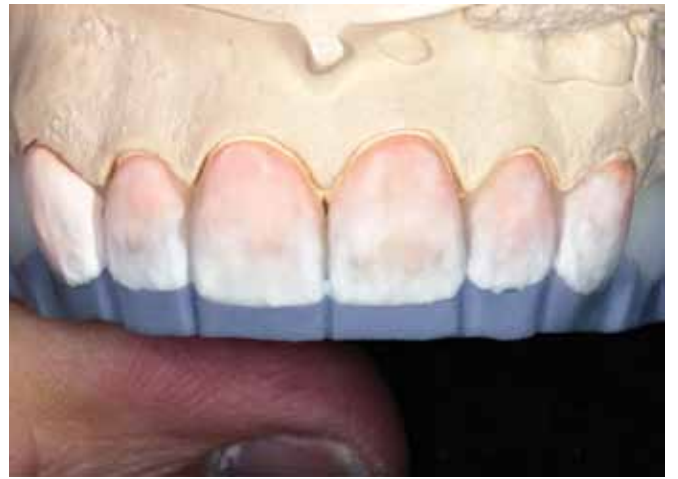

Figure 27: First layer finished with complete overlay of porcelain.

Transparent Blue Fluorescent by itself, and Opal 4, which is a Transparent Amber powder (Fig 26). Transparent Blue was used in the mesial and distal grooves of ##7-10, and the mesial line angles of #6 and #11. Opal 2 was used to fill #6 and #11 to contour, and to fill the incisal length of #7 and #10.

The lubricated matrix was placed over the wet porcelain, which was carefully blended toward the gingival with Opal 2 at about 3 mm to 4 mm from the incisal edge. At this point, micro-layering with a mix of Opal 1 and Opal 2 was used to complete all the restora-

tions to full contour (Fig 27). The interproximals were sliced, and contacts were not added.

The restorations were fired at 785° C under vacuum and held in air for one minute. The units were placed back on the model (Fig 28) and the matrix re-lubricated.

The 50/50 mix was added to the mesial and distal, .5 mm taller than the restorations. Then, Opal 4 was used to mimic the amber incisal edge, going from mesial to distal (Fig 29). The matrix was seated, after which that blend was completed using Opal 2. The 50/50

mix was applied to create the final contour and line angles of the teeth and, once sliced, .5 mm of the 50/50 mix was added to the mesial and distal corners of ##7-10.

The restorations were fired at 780° C under vacuum with a one-minute hold under air (Fig 30). The contacts were fit, and the buildup matrix was sprayed (Quickcheck Red) and fit back onto the solid model; then the temporary matrix was sprayed and fit to verify the accuracy of the length compared to the approved temporaries.

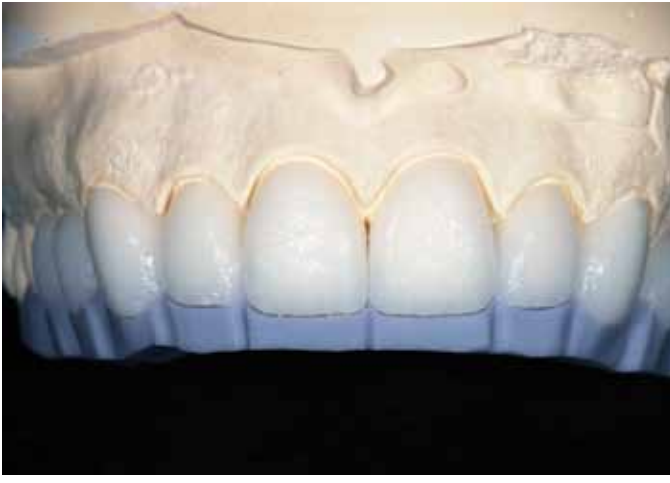

Figure 28: First layer of porcelain fired.

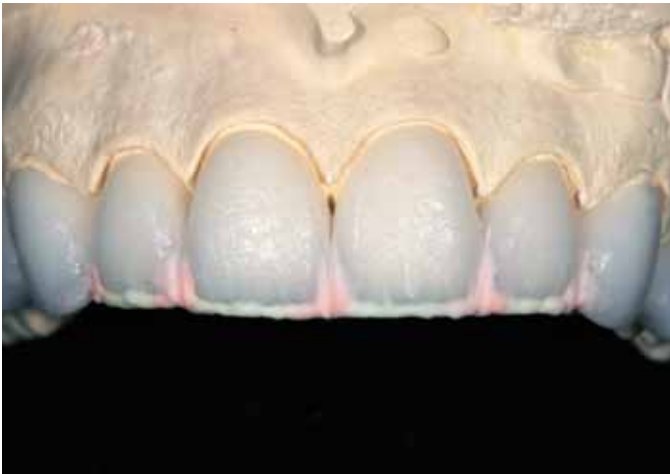


Figure 29: Second layer started; pink = 50% Opal 1 + 50% Opal 2; yellow = Opal 4 (amber).

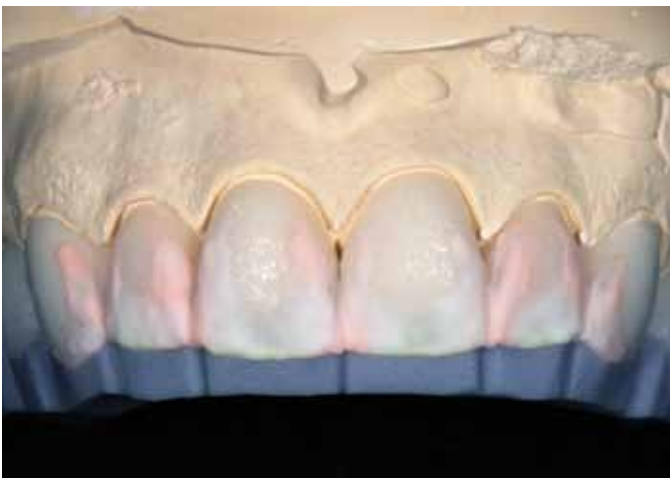

Figure 30: Second layer complete.

Burs (863.HP.012, 850.HP.016, Komet) were used to create tooth morphology, anatomy, and surface texture, after which a low-fusing glaze (Authentic) was applied and the units fired at 710° C in air. The contacts and occlusion were checked with Accufilm, and all units were polished with a #12 Buffalo bristle brush (Abbot-Robinson, Pearson Dental; Sylmar, CA) with Diashine fine-grit polisher (VH Technologies; Lynnwood, WA) (Fig 31). The units were etched and returned to the dentist for delivery to the patient.

Cementation

Upon return from the ceramist, the porcelain restorations were inspected on the dies for marginal fit and on solid models for proper interproximal contacts. They were also inspected under magnification for any possible packing and shipping damage. Profound anesthesia was obtained through the use of a topical anesthetic, followed by infiltration injections at #4 and #13 and bilateral anterior middle superior alveolar injections of articaine with 1:100,000 epinephrine to allow the patient more control of her lip during and after the seating appointment. The provisional veneers were removed with a scaler and hemostats. The preparations were pumiced to clean off any residual resin, temporary material, or debris. The veneers were then tried into the patient's mouth and evaluated for fit and esthetics (first individually, then collectively with a glycerin-based try-in gel). The patient then viewed her smile in a hand mirror. No adjustments were needed and the patient approved the esthetic appearance.

The veneers were removed from the patient's mouth and carefully cleaned and re-etched to remove any possible contamination. The veneers were then placed in an ultrasonic cleaner under distilled water for three minutes.

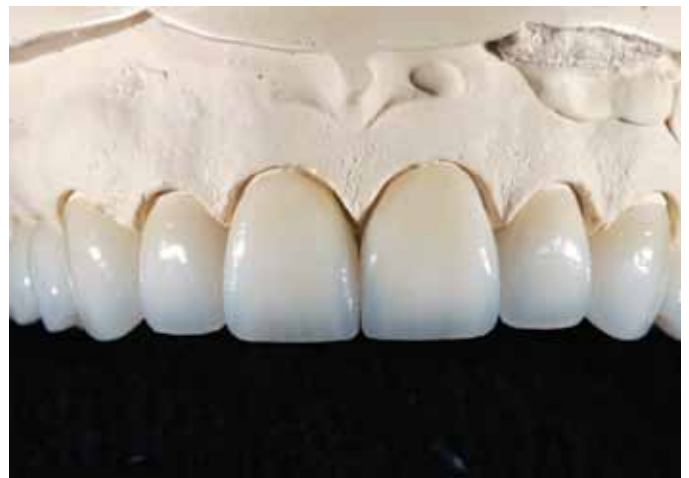

Figure 31: Completed stained and glazed restorations on solid model.

CLINICAL COVER STORY



Figure 32: The patient's restored smile.

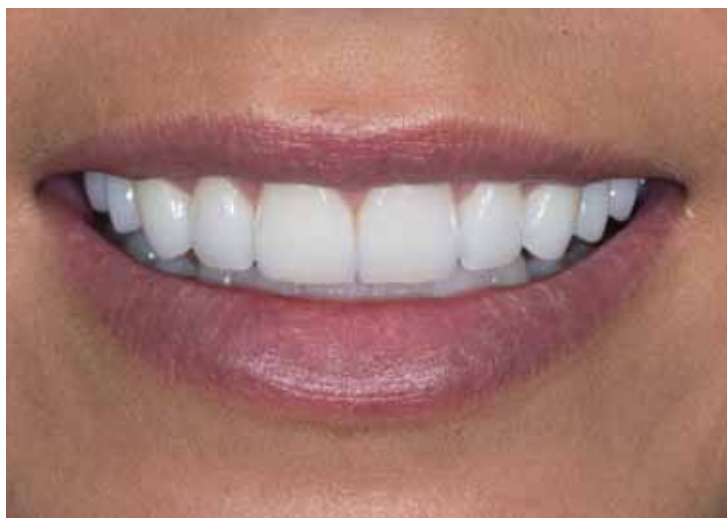

Figure 33: The restored full smile demonstrates proper progression of incisal embrasures and treatment of buccal corridors.

She was excited by the idea of having her teeth restored in a conservative manner, without having to pursue prolonged orthodontic treatment.

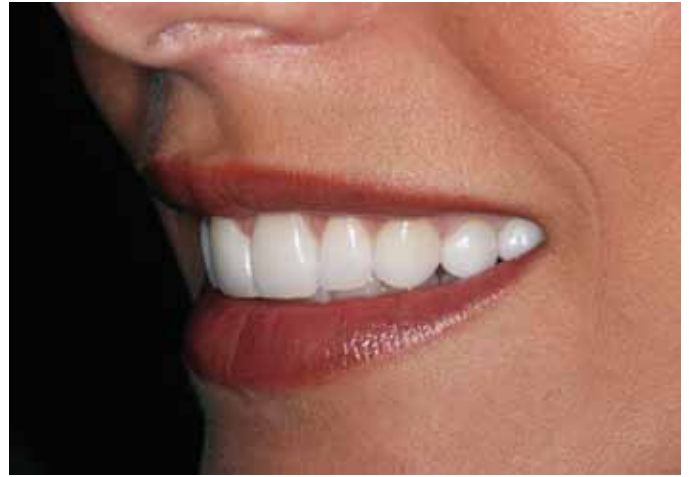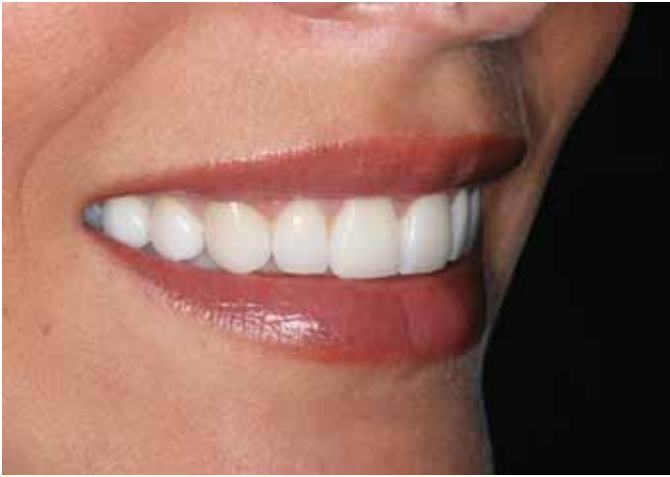Upon removal from the water, they were dried with oil-free compressed air, and silane coupling agent (Ultradent) was applied to the intaglio of the veneers.⁹ After one minute they were dried again and a thin coating of Excite bonding agent (Ivoclar Vivadent) was applied to the inside of the veneers and air-thinned. RelyX Translucent Veneer Cement (3M ESPE; St Paul, MN) was applied to the veneers and they were immediately placed into a ResinKeeper light-safe box (Cosmedent) to prevent polymerization of the resin.^{3,4}

A split rubber dam was applied to isolate the prepared teeth from the oral environment. The preparations were then acid-etched for 15 seconds and the 35% Ultra-Etch phosphoric acid gel etchant (Ultradent) was removed with a copious air and water spray.^{3,4} All preparations were lightly dried, but not desiccated, with oil-free compressed air.^{3,4} The preparations were left moist and bonding agent was applied to each preparation and agitated for 20 seconds prior to air-thinning to evaporate solvents. The bonding agent was then cured for 20 seconds with a Fusion LED curing light. The veneers were removed from the light-safe box and seated on their respective preparations. Excess cement was removed with a Regular Microbrush (Grafton, WI) and they were tacked into place for five seconds each with the LED curing light.¹⁰ Additional excess was gently removed with a scaler, floss was passed through the contacts in the apical direction only, and the veneers were cured fully for an additional 30 seconds each.¹⁰ The margins were inspected and any excess cured cement was removed with a #12 scalpel blade.¹⁰ Interproximal areas were cleaned with EpiteX finishing strips (GC America; Alsip, IL). DeOx oxygen-inhibiting gel (Ultradent) was placed around all margins and the restorations were cured an additional 10 seconds to finalize polymerization.^{3,4,9} Rubber dam isolation was removed and occlusal marking paper was used to evaluate the occlusion in CO and in excursive movements. The lingual aspect was then polished with diamond paste and Flexi-Buff polishers (Cosmedent) in a slow-speed handpiece.

The patient's teeth were inspected again for any excess restorative material. The occlusion was checked again and smooth, proper contacts were verified with unwaxed floss.

The patient returned the following day and her functional occlusion was evaluated and her teeth were inspected for any residual cement. Also at this 24-hour postoperative check appointment, maxillary and mandibular alginate impressions were made along with a PVS bite registration to be used for fabrication of a maxillary full-arch bite guard for nighttime wear.³

CLINICAL COVER STORY



Figures 34a & 34b: Restored right and left lateral full-smile images demonstrate proper progression of incisal embrasures.

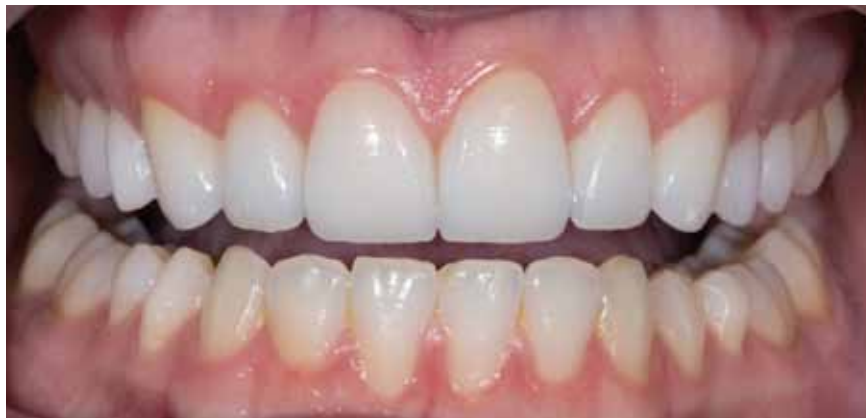
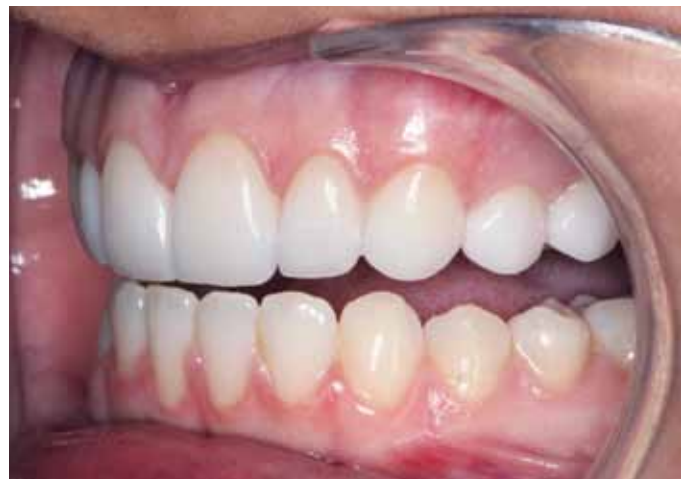
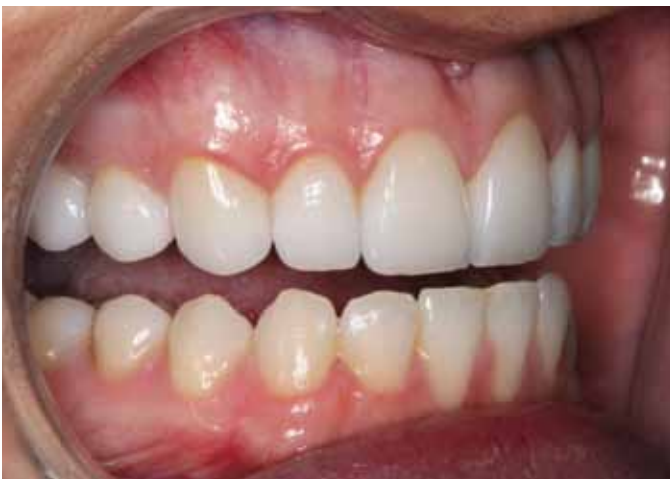Figure 35: Restored retracted 1:2 view demonstrates proper shape and proportions, resulting in a more harmonious smile.



Figures 36a & 36b: Restored right and left lateral retracted 1:2 views exhibit a more harmonious progression of incisal embrasures and transition from the anterior to the posterior.

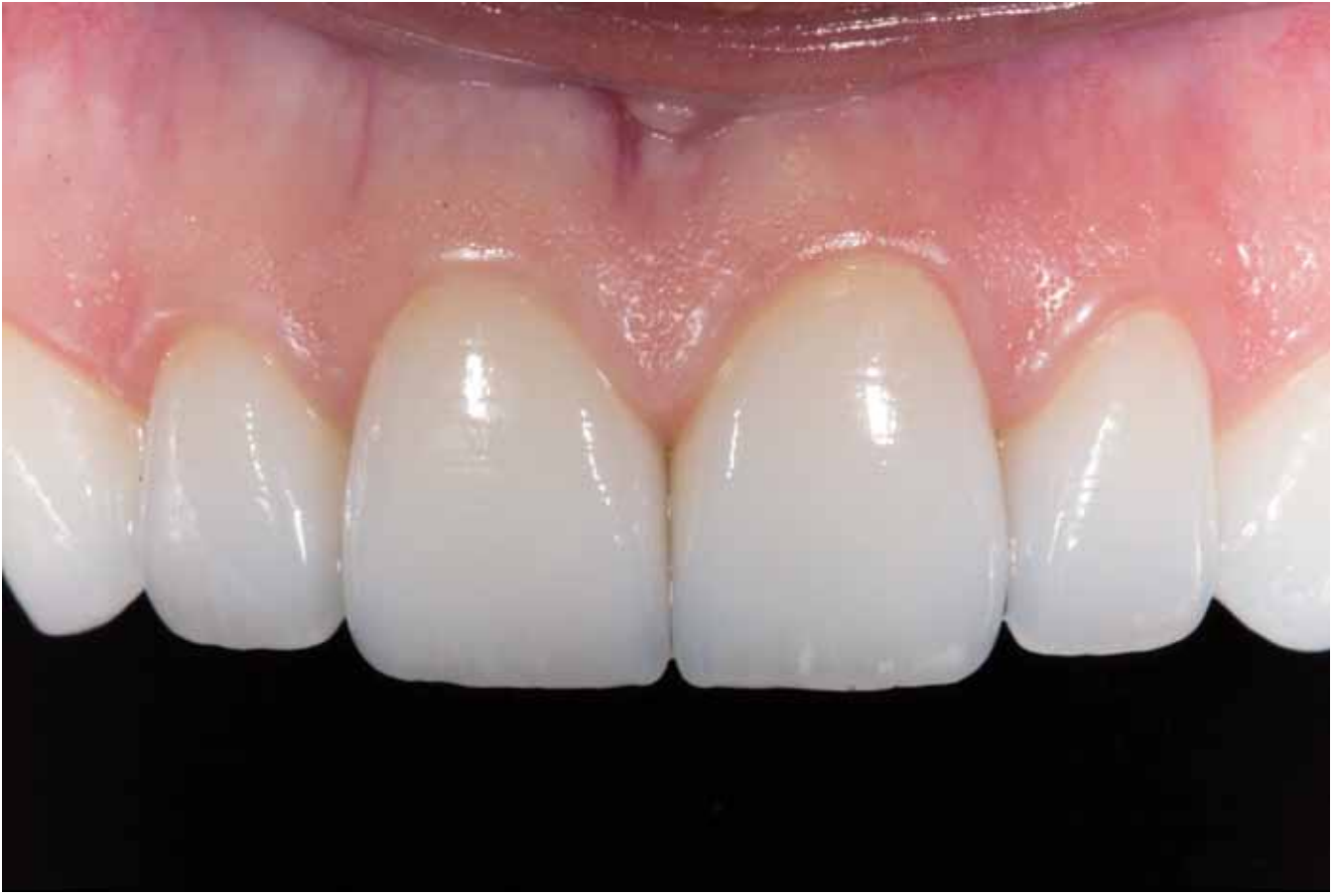
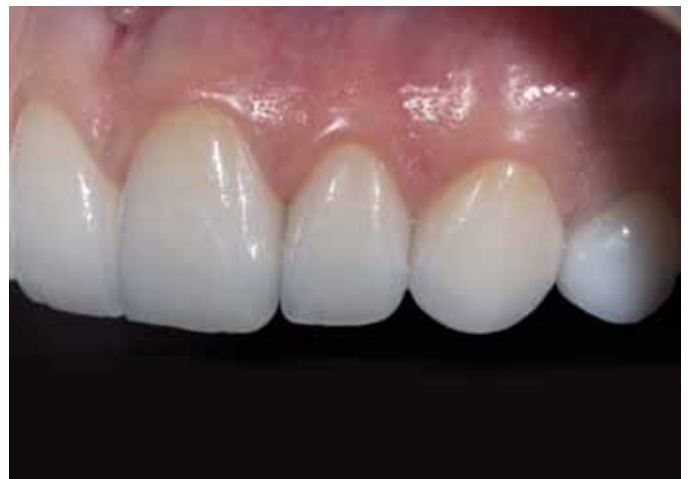
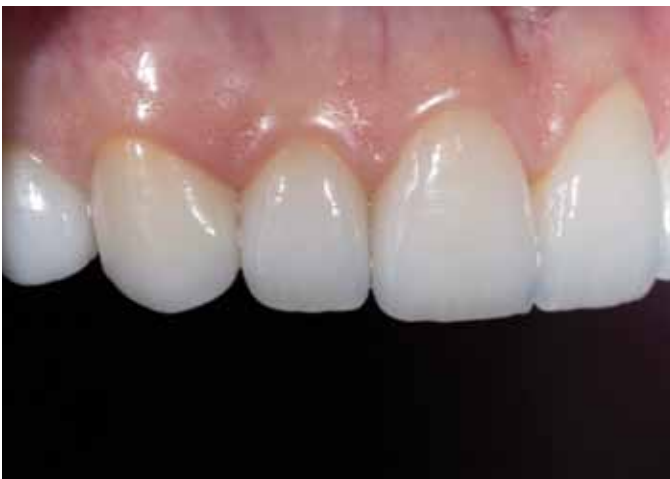Figure 37: Restored retracted 1:1 view demonstrates proper shape and proportion, resulting in a more harmonious smile. The distal incisal developmental defect on #9 has been corrected to mirror the appearance of #8.



Figures 38a & 38b: Restored retracted right and left lateral 1:1 views demonstrate proper shape and proportion, resulting in a more harmonious smile. The distal incisal developmental defect on #9 has been corrected to mirror the appearance of #8.

CLINICAL COVER STORY

Postoperative home care instructions were given and the patient was scheduled for a follow-up appointment for radiographic and photographic documentation, a final check for function and esthetic evaluation, and delivery of the maxillary protective bite guard³ (Figs 32-40).

Conclusion

Porcelain veneers can be employed to provide beautiful, natural, long-lasting functional cosmetic results. This patient presented with some very precise requests. Careful planning, great communication, and meticulous use of contemporary dental materials yielded an excellent result that surpassed the patient's expectations.

References

1. American Academy of Cosmetic Dentistry. Diagnosis and treatment evaluation in cosmetic dentistry: a guide to Accreditation criteria. Madison (WI): The Academy; 2001.
2. Dawson PE. Evaluation, diagnosis, and treatment of occlusal problems. St. Louis (MO): Mosby; 1989.
3. Magne P, Belser U. Bonded porcelain restorations in the anterior dentition: a biomimetic approach. Hanover Park (IL): Quintessence Pub.; 2002.
4. Gurel G. The science and art of porcelain laminate veneers. Hanover Park (IL): Quintessence Pub.; 2003.
5. Rufenacht CR. Fundamentals of esthetics. Hanover Park (IL): Quintessence Pub.; 1992.
6. Fradeani M. Esthetic analysis: a systematic approach to prosthetic treatment. volume 1. Hanover Park (IL): Quintessence Pub.; 2004.
7. Goldstein RE. Esthetics in dentistry. Hamilton (ONT, CA): B.C. Decker; 1998.
8. Flax H. Smile enhancement with laser technology—predictable and esthetic: a case report. *J Cosmetic Dent.* 2007;23(1):92-8.
9. Touati B, Quintas AF. Aesthetic and adhesive cementation for contemporary porcelain crowns. *Pract Proced Aesthet Dent.* 2001;13(8):611-20.
10. Miller MB. Reality: the techniques: volume I. Houston (TX): Reality Publishing; 2003. **JCD**

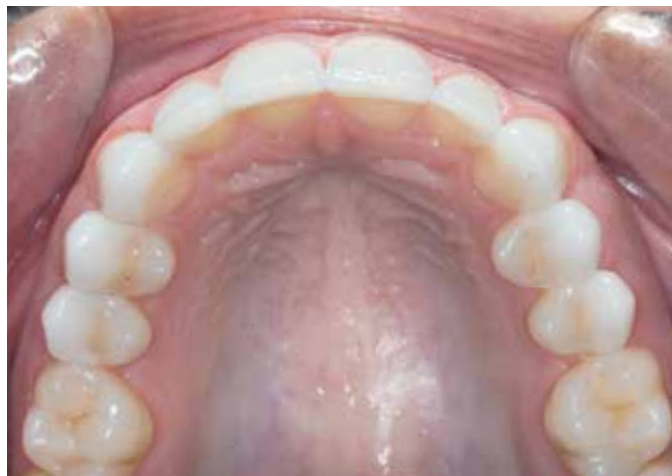

Figure 39: Maxillary postoperative occlusal view demonstrates corrected arch form and proper facial embrasures.

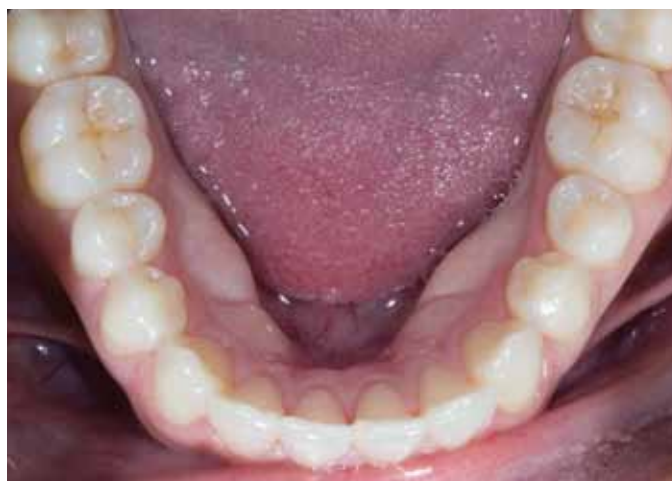

Figure 40: Postoperative mandibular occlusal view demonstrates no changes.



Dr. Rowe is an AACD Accredited Member, an AACD Accreditation Examiner, and a member of the American Board of Cosmetic Dentistry. He graduated from the University of Tennessee College of Dentistry in 2000 and owns a practice with his wife, Dr. Kristy Rowe, in Jonesboro, Arkansas.

Mr. Payne owns a dental laboratory in San Clemente, California, and is an Accredited Member of the AACD.

Disclosures: Dr. Rowe serves as a clinical evaluator for DMG America. Mr. Payne did not report any disclosures.